

# **VETCare**

*Veterinary Emergency & Specialist Care Center*

## Inside:

- Case Report: Adrenal Tumors
- McDreamy — Just Like New!
- IAMS Pet Imaging Center

SPRING 2007

[www.EmergencyVetCare.com](http://www.EmergencyVetCare.com)

## VetCare Celebrates 10th Anniversary!

VetCare is proud to announce we are celebrating our 10<sup>th</sup> year as a member of the Tri Valley community in 2007. Dr. Barry Kipperman founded VetCare April 1, 1997 with the belief that there was a need for a 24 hour emergency and specialty referral center. It has been a



pleasure and honor helping the many Tri Valley families care for their four legged family members over the past 10 years. We appreciate the support of the community and the kind support of our local veterinary community who have utilized our referral services.

## News and Notes

### Face Lift

A special thanks to all of our clients for hanging in there during our mini remodel. We recently updated the look in our exam rooms, reception area and lobby with new paint, wall paper, laminate surfaces, and carpeting. This was especially challenging for all involved as we were seeing patients throughout the entire process.

### RACE Approved Continued Education

VetCare has been working hard so that we can bring RACE approved continued education opportunities to our local referral community. Each month we are hosting a medicine and surgery lunch time “rounds.” If you have not received our fax regarding the dates and topics of these free CE events and are interested in knowing when they are being held please contact our front desk or Susan Hatch at 925-556-1234 or [shvetcare@yahoo.com](mailto:shvetcare@yahoo.com) and we will gladly add you to our notification list. Lunch provided!

### Winston — A Pug at Work



As some of you know, Winston is Dr. Kipperman's two year old male pug. Winston is much loved by the team and is featured now in a series of get well post cards we send to patients seen at our facility. Winston will do anything for a dog kibble and loves to ham it up in front of the camera.

## VSCD Surgeon Passes Board Exams



We are very proud to announce that Dr. Gregory Marsolais is now a Diplomate of the American College of Veterinary Surgeons. Dr. Marsolais looks forward to continuing his work with Veterinary Surgical Centers of the Delta at their VetCare location. Please give him a call if you have a case in need of surgical services.

## VSCD Mobile Surgical Services



VSCD is pleased to announce mobile surgical services to the Tri-Valley area. We live here. We work here. We want to grow with you! Please call VetCare 925-556-1234 and speak with Dr. Haburjak or Dr. Marsolais directly regarding this new service!

## VetCare Nurses Achieve RVT Status

We are happy to announce that two of our nursing team members have recently received their RVT licenses: Amy Chionis one of our full time Nursing Supervisors and Deb Hines one of our key relief nurses. We are proud of their hard work and success in achieving their licensure.

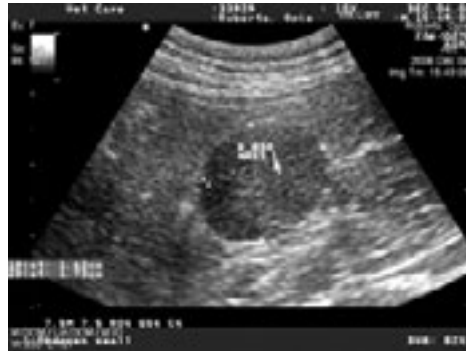# Adrenal Tumors

In early December, "Opie" a 10 year old MN DSH, presented to the VetCare emergency service for a two day history of lethargy and anorexia. Opie's examination findings included marked ventroflexion of his neck and generalized weakness. A biochemical profile revealed a potassium of 2.3 mEq/L (normal range is 3.5-5.5) and urine specific gravity of 1.022. Radiographs of thorax/abdomen were unremarkable. Possible causes for hypokalemia include potassium-losing nephropathy, GI losses, severe alkalosis, and mineralocorticoid-secreting tumor. Supportive care included IV Lactated Ringers solution with supplementation of KCL at 60 meq/L. Despite fluid administration rates of two to three times maintenance, serum potassium values only increased to 3.0 mEq/L in the first 24 hours. Opie did begin to show improvement in strength.

Opie was supported overnight and transferred to Dr. Kipperman's care for an internal medicine consult. At that time, his cervical ventroflexion had resolved. Additional diagnostics included abdominal ultrasound which revealed a 2cm x 2cm, well-circumscribed right adrenal mass (Figure 1). Close association with the caudal vena cava was noted and there was no evidence of vascular invasion. A tentative diagnosis of aldosterone-secreting adrenal tumor was made. Intravenous potassium supplementation was increased to 80mEq/L, and Opie was started on oral potassium gluconate. Blood pressure measurement revealed hypertension with an average of 180mm. Aldosterone assays were submitted. Despite aggressive potassium supplementation, potassium values only increased to 3.5mEq/l (low normal).

Two days after admission, Opie was transferred to Dr Marsolais for exploratory laparotomy and adrenalectomy.

During surgery, the right adrenal mass (Figure 2) was found and adrenalectomy performed. Opie recovered well and was supported with IV fluids, antibiotics



**Figure 1**

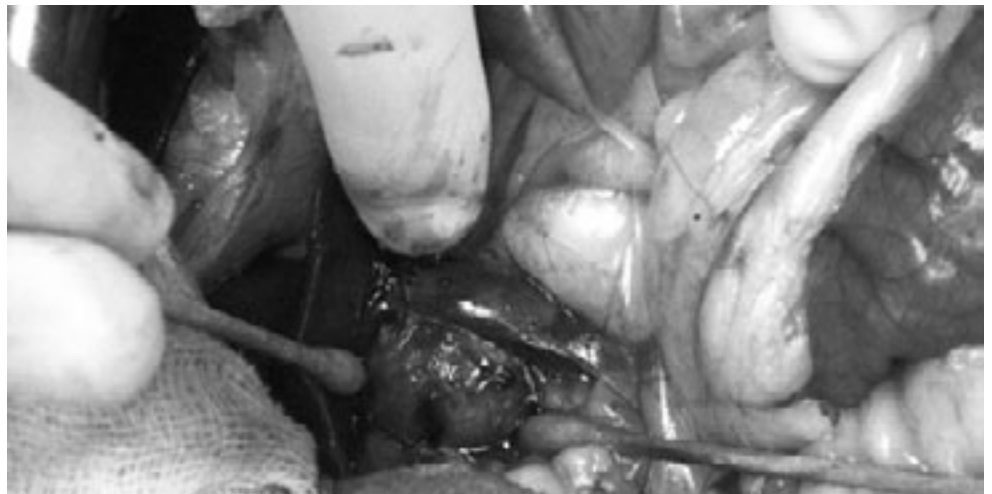
and Buprenex for pain. Within 24 hours, Opie was eating and drinking and was discharged the next day on Tumul-K and oral Buprenex. Histopathology confirmed adrenocortical carcinoma. At one week post-op, electrolyte evaluation documented Opie to have a normal potassium of 4.4mEq/L. Subsequent weekly evaluations documented stable potassium at 5.3mEq/L. Aldosterone assays documented dramatically elevated levels in the face of a low serum potassium, compatible with an aldosteronoma.

Adrenal tumors are being identified

with increasing frequency, due to the widespread availability of ultrasound. Most of these are noted in dogs, and are either incidental, or associated with signs of Cushing's syndrome. Aldosterone-secreting adrenal tumors are very rare in cats, with only sporadic reports in the literature. These typically cause hypertension and profound hypokalemia, both due to secondary effects of excessive aldosterone. The most common cause of hypokalemia in cats is chronic renal failure. For Opie, the absence of azotemia made this diagnosis unlikely and prompted the recommendation for ultrasound to screen for an adrenal mass.

Opie's prognosis is good based on complete excision of his adrenal tumor. Potassium supplementation remains the hallmark of postoperative treatment and can be difficult to manage. Opie's potassium supplementation will be tapered gradually. His owners are currently happy to report a healthy, affectionate cat at home. Opie's care exemplifies the synergy between our emergency, internal medicine, and surgical services to benefit your patients.

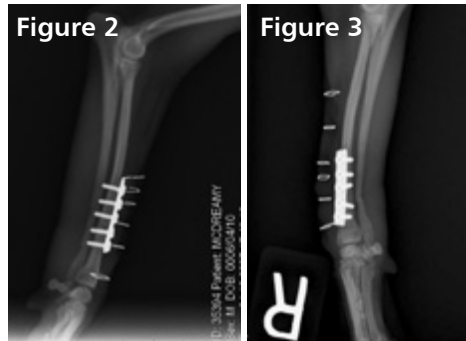
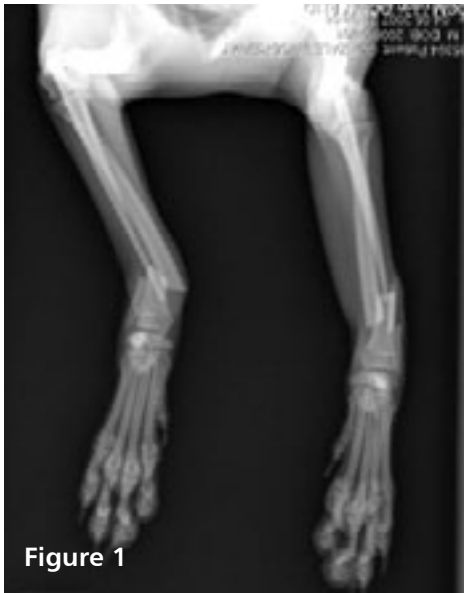Thanks to Dr Linda Bloomfield and Dr. Jerry Bird of Livermore Veterinary Hospital for their referral of Opie.



**Figure 2**

# McDreamy — Just Like New!

On April 5, 2007 little McDreamy fell from a ladder at home. McDreamy, a cute black and white male Chihuahua, suffered from fractures to the bones in both front legs (bilateral radius/ulna fractures –figure 1). The injuries were significant and required surgical intervention. Realizing that McDreamy



needed far more care than his family could afford, his owner approached the Valley Humane Society for assistance. It became clear to McDreamy's family that they were not going to be able to provide the home care and financial care for McDreamy and they opted to surrender him to the Valley Humane Society.

Veterinary Surgical Centers of the Delta and VetCare worked together with the Valley Humane society to provide the necessary surgical intervention and medical care to repair McDreamy's fractured legs. Dr. Gregory Marsolais, DVM, MS, Dipl. ACVS performed

the surgical repair here at VetCare and placed plates and screws to stabilize the fractures (figure 2 & 3). McDreamy will be recovering in the loving care of a Valley Humane Society foster home prior to being placed for adoption (figure 4).

If you would like to help the Valley

Humane Society you can send a donation directly to Valley Humane or you can mark the donation to go towards their Just Like New Fund



which helps provide medical care to needy pets: Valley Humane Society 3670 Nevada Street, Pleasanton, CA 94566 (925) 426-8656. VetCare and Veterinary Surgical Centers of the Delta were proud to assist the Valley Humane Society in finding a solution to McDreamy's medical problem.

## IAMS Pet Imaging Center

On March 14th members of the staff and doctors of VetCare and VSCD were invited to tour the IAMS Pet Imaging Center located in Redwood City (a 30 minute drive from VetCare). The evening was hosted by Tina Lee, Sr. Account Executive and Kim Hyde, Operations Manager. We toured the entire facility and viewed the MRI magnet. Pat Gavin, DVM, PhD, Diplomate of the ACVR, produced an informative presentation on the varied and powerful imaging options of their 1.5 Tesla magnet as well as his interpretive services.

The facility was beautiful and both client and pet friendly. Most cases are estimated to be in and out in about two hours depending on the area(s) imaged. The visit includes a pre-anesthetic exam, sedation, the imaging process and recovery time.



A highlight of the evening was viewing the multiple images of a patient that Doctors Marsolais and Kipperman had sent for imaging. The dog presented with Caval Syndrome that had responded well to steroids and was a possible surgical candidate. The Thymoma was clearly visible on the MRI which also showed the great extent of the invasiveness. This led to the conclusion that the thymoma was not resectable. MRI

allowed the correct decision to be made.

VetCare looks forward to continuing our relationship with the IAMS Pet Imaging Center so that we can provide the best possible diagnostic options for our clients and their pets.





7660 Amador Valley Blvd  
Dublin, CA 94568

Phone: 925-556-1234  
Fax: 925-556-1229  
Email: shvetcare@yahoo.com  
Web: www.EmergencyVetCare.com

Barry Kipperman, DVM, DACVIM  
Gerardo Martin DelCampo, DVM  
River May, DVM  
Cheryl Ramos, DVM  
Britta Revels, DVM

John J. Haburjak, DVM, DACVS  
Gregory S. Marsolais, DVM, MS, DACVS  
Kimberly R. Carlson, DVM

## New After Hours Direction Stickers

We have new window stickers (static cling) that can be used to direct clients to our emergency center when your practice is closed. If you have not received one or more of these we will be happy to send one to you, just give us a call!

**If We Are Closed...**  
and your pet has a  
**Medical Emergency, please go to**



*Veterinary Emergency & Specialist Care Center*  
**7660 Amador Valley Boulevard**  
in Dublin

**Open 24 Hours**  
**For Directions Call:**  
**(925) 556-1234**

